Injectable Soft Tissue Augmentation 158

Amelia K. Hausauer and Derek H. Jones

Chapter Contents

Historical Perspective 2692
General Injection Protocols 2692
Injectable Soft Tissue Filler Materials 2694
Platelet-Rich Plasma 2699
Complications 2699

Key features

- Fillers are used to soften the appearance of superficial wrinkles and to recontour and smooth the deep folds of the face
- Other indications include reducing the appearance of atrophic, traumatic, and acne scars; lip augmentation; and volumizing the face in areas of lipoatrophy or senescence-associated fat loss
- Agents include hyaluronic acid derivatives, synthetic materials, autologous fat, and platelet-rich plasma
- Selection of an agent depends on the size, depth, and location of the volume deficiency as well as the cost and longevity of the product
- Agents are injected into the dermis, subcutaneous fat, or supra-periosteal space via a needle or cannula; various techniques, such as serial puncture, linear threading, fanning, cross-hatching or depot injection, are utilized and require an understanding of anatomy and best injection practices
- Fillers can be used as monotherapy or as an adjunct to other rejuvenating injectable techniques or surgical procedures in order to maximize longevity and aesthetic correction
- Complications are technique-dependent or material-related, and include hypersensitivity reactions, granuloma formation, bacterial biofilms, contour irregularities, and vascular occlusion, in addition to common injection-related phenomena such as pain, edema, and purpura

CAUSES OF CUTANEOUS DEFECTS AND CONTOUR CHANGES AMENABLE TO FILLERS FOR CORRECTION
Chronologic aging
• Loss of subcutaneous fat • Gravity • Bone resorption (e.g. mandible, maxilla, zygoma)
Photodamage
• Degradation of collagen, elastin, hyaluronic acid, and other components of the extracellular matrix leading to decreased skin turgor and rhytides
Other
• Exercise-induced lipoatrophy • Scarring (e.g. due to acne, varicella, trauma, surgery) • Inflammation (e.g. lipoatrophy due to lupus panniculitis or other panniculitides; see Ch. 100) • Lipodystrophy (inherited, acquired, drug-induced; see Ch. 101)

Table 158.1 Causes of cutaneous defects and contour changes amenable to fillers for correction.

SOFT TISSUE AUGMENTATION INDICATIONS
FDA-approved (see Table 158.4 for indications for specific products)
• Moderate to severe facial wrinkles and folds, such as nasolabial folds • Submucosal implantation for lip augmentation and perioral rhytides • Deep injection for cheek augmentation to restore age-related volume loss in the midface • Volumization of the dorsal hands • Chin augmentation to improve prominence and profile • HIV-associated lipoatrophy • Acne scars
Off-label
• Non-dynamic rhytides and folds – nasojugal folds, marionette lines, glabellar folds, etched-in radial cheeks lines, horizontal neck rhytides • Volume deficits – lipoatrophy (including buttocks and body deficits), sunken temples, tear trough deformity, atrophic earlobes • Structural prominences – jawline, nasal bridge, lateral eyebrow elevation • Distensible scars – trauma, surgery • Skin laxity • Nipple contouring

Table 158.2 Soft tissue augmentation indications. FDA, US Food and Drug Administration.

Interventions for the aging face can be broadly categorized into the four "R's" of facial rejuvenation: **R**esurfacing (chemical peels, dermabrasion, and ablative and non-ablative lasers); **R**edraping (the various pulling and lifting facial surgical procedures); **R**elaxing (chemodenervation with paralytic agents); and **R**eplacement/**R**econtouring (the use of filling agents for superficial and deep soft tissue augmentation). This fourth "R" has witnessed remarkable growth as patient demand for safe and effective minimally invasive aesthetic techniques has increased. In concert, the number of available dermal fillers and agents for soft tissue augmentation has expanded exponentially. More recently, there has been a shift from filling wrinkles and lines to replacing volume loss associated with atrophied fat and bone[1].

Patients often do not adequately appreciate the degree and significance of their volume deficit and must first be educated about the underlying anatomy of what is producing their "wrinkle". In addition to explaining the significance of volume deficits adjacent to the areas of primary concern, a distinction must be made between dynamic versus static lines as well as cutaneous changes due to photodamage versus those due to chronologic aging (senescence) (Table 158.1). Although these defects often appear in combination, they must be assessed individually. Patients should be made aware of newer, commercially available injectable products so that the physician is able to personalize their treatment and cater to subtle nuances of their faces. Many of the newer products have unique characteristics and indications that make them more suitable for certain patients (Table 158.2).

While the type of defect is clearly important, so are its size, depth, and location, in addition to the appearance and integrity of the adjacent tissue. A discussion regarding therapeutic options should include alternatives such as surgery (e.g. rhytidectomy, excision), resurfacing (see Ch. 137), and chemodenervation agents (see Ch. 159), as well as no intervention at all. Patients should understand the indications, technique, advantages, disadvantages, and inherent risks of each procedure, and they should be given an estimate of the financial cost and "downtime". As with any treatment, the degree of overall success is largely proportional to the creation (and achievement) of realistic and appropriate goals and expectations. Patients undergoing elective rhytide effacement and optimization with injectable fillers must realize that replacing lost or atrophic subcutaneous tissue is often temporary. Monotherapy with

Downloaded for Anonymous User (n/a) at Egyptian Knowledge Bank from ClinicalKey.com by Elsevier on March 10, 2024. For personal use only. No other uses without permission. Copyright ©2024. Elsevier Inc. All rights reserved.

one agent may not be adequate, and multiple agents may be required. All wrinkles are not created equal; they come in many shapes and sizes, and there is no one filler agent that is suitable for all defects. The choice of an appropriate dermal or subcutaneous implant requires knowledge of the available options and their characteristics.

HISTORICAL PERSPECTIVE

Dating back to 1893, Neuber used blocks of autologous fat harvested from the arms for tissue augmentation of depressed facial defects. Eighteen years later, Brunings first described using the syringe technique to transfer free fat. Then, in 1953, Baronders published a review of permanent soft tissue augmentation with liquid silicone. Finally, in 1981, bovine collagen became the first US Food and Drug Administration (FDA)-approved xenogeneic agent for soft tissue augmentation, and it remained the standard filler for over 20 years (Table 158.3).

In 1981, Zyderm® I was the first bovine collagen filler, followed by Zyderm® II and Zyplast®. As a group, they have a long safety track record having been used in more than a million patients[2]. All three were derived from a closed US cattle herd carefully monitored to prevent transmission of bovine spongiform encephalitis, a prion-mediated disease. Cutaneous hypersensitivity reactions occurred in 3% of patients; therefore, pre-treatment skin testing became mandatory[3]. The longevity of these bovine collagen fillers was ~2–3 months. Bovine collagen is historically important as it set the standard against which the next generation of soft tissue fillers was initially compared.

In an attempt to reduce the risk of hypersensitivity reactions, a series of dermal fillers were developed that did not require skin testing, some of which were longer lasting – CosmoDerm®/CosmoPlast® (bioengineered human collagen); Evolence® (porcine type I collagen, potentially lasting up to one year)[4]; and a family of injectables from preserved particulate cadaveric connective tissue (Dermalogen®, Cymetra®, and Fascian®). With the exception of Renuva®, an allograft adipose matrix, most are no longer commercially available due to high manufacturing costs and low demand.

In 2003, the FDA approved Restylane®, which ushered in a new era of agents made from hyaluronic acid (HA). Many of the HA formulations proved to be superior in longevity compared to their collagen predecessors and had more feasible manufacturing. Globally, HA quickly became the most popular soft tissue filler. Currently available FDA-approved formulations of HA are outlined in Table 158.4. Historic HA formulations that are no longer available in the US are listed in Table 158.3.

TEMPORARY SOFT TISSUE FILLERS THAT ARE NO LONGER AVAILABLE IN THE US
Bovine-derived collagen
• Zyderm® I, Zyderm® II, Zyplast®
Porcine-derived collagen
• Evolence®
Non-cadaveric human collagen
• CosmoDerm® 1, CosmoDerm® 2, CosmoPlast®
Autologous human collagen
• Autologen®
Cadaveric human collagen
• Dermalogen®, Cymetra®
Cadaveric fascia lata
• Fascian®
Cadaveric adipose matrix
• Renuva®
Porcine-derived gelatin
• Fibrel®
Avian-derived hyaluronic acid
• Hylaform®, Hylaform Plus®
Non-animal stabilized hyaluronic acid
• Captique®, Elevess®, Prevelle Silk®
Autologous fibroblast therapy
• Isolagen®

Table 158.3 Temporary soft tissue fillers that are no longer available in the US. This is due to discontinuation by the manufacturer or decreased demand because of popularity of other products.

GENERAL INJECTION PROTOCOLS

Prior to performing any filler procedure, injectors must have a firm grasp of vascular anatomy to ensure safety and help guide optimal injection techniques and product selection. This forms the foundation of all treatments; its importance cannot be overemphasized, since accidental injection into facial arteries can have catastrophic consequences, as outlined by the American Society for Dermatologic Surgery (ASDS) Task Force on evidence-based guidelines for prevention and treatment of adverse events from injectable fillers[5]. While intravascular injection is possible at any location on the face (e.g. lips' labial arteries), the nose, glabella, forehead, superior nasolabial fold, and medial cheek are considered significant danger zones, from highest to lowest, for vascular complications, visual compromise, and cerebrovascular events[6,7].

Studying anatomy and appreciating its variability are the underpinnings of all injection techniques, which vary by location, and represent a life-long learning endeavor. The facial artery is a branch of the external carotid artery that crosses the jawline periosteally at the antegonial notch just anterior to the border of the masseter muscle (see Fig. 142.3). It takes a circuitous course deeply from the lower lateral cheek to the nasolabial fold, branching off as the inferior and superior labial arteries, then becoming the angular artery near the superior nasolabial fold (see Fig. 142.15). More superficially, the angular artery runs along the medial cheek/lateral nose in variable patterns[8]. It anastomoses with four arteries: (1) dorsal nasal artery; (2) distal ophthalmic artery, which connects to the retinal and cerebral vasculature; (3) supratrochlear artery; and (4) supraorbital artery; the two latter arteries are end branches of the distal ophthalmic artery. The supratrochlear and supraorbital arteries traverse the supraorbital ridge periosteally at the glabella and medial brow, respectively, then run superiorly toward the scalp. These pathways explain the danger zones referenced above[5].

There is no one completely safe injection protocol only safer strategies based upon location, which are briefly outlined here.

Nose, Glabella, and Forehead

These three regions present the highest risk. Therefore, to minimize the potential for disastrous outcomes, only the most experienced injectors should approach treatment in these areas. Although rare, the chance of blindness is greatest with nasal injections into the dorsal nasal artery. Based on cadaveric studies, the safest plane on the dorsal nose appears to be pre-periosteal or pre-perichondrial[9]. Yet, due to vascular variability, the dorsal nasal artery may lie on the midline periosteum[10].

The glabella also carries higher risk because of the periosteal exit of the supratrochlear and supraorbital arteries. Injecting deeply within this region is contraindicated. Experts may consider correcting glabellar rhytides that do not respond to neuromodulators with intradermal injections using small needles. However, the vessels are variable, potentially running more superficially, especially in those with thin tissue[11,12]. These arteries course cephalad to caudal and surface superficially within the frontalis muscle superior to the brow. Consequently, forehead correction is safest with cannulas placed in the pre-periosteal, subgaleal plane at least 2 cm superior to the orbital rim and in a horizontal direction, perpendicular to the vasculature.

Nasolabial Fold, Cheek

Two additional danger zones are: (1) the superior nasolabial fold where the angular artery becomes subcutaneous; and (2) the cheek medial to the midpupillary line (medial cheek), where the infraorbital artery runs periosteally and the angular artery subcutaneously. Both needles and cannulas are FDA-approved for injection in these regions, but given the different vascular depths and pathways, a cannula with a minimum size of 25-gauge (G) may be safer (see below)[13–16]. In contrast, the lateral cheek along the zygomatic prominence is considered less risky, although the zygomaticofacial artery does sit on the periosteum. Injection along the periosteum with a needle or cannula is appropriate[5].

Downloaded for Anonymous User (n/a) at Egyptian Knowledge Bank from ClinicalKey.com by Elsevier on March 10, 2024. For personal use only. No other uses without permission. Copyright ©2024. Elsevier Inc. All rights reserved.

FDA-APPROVED INDICATIONS FOR SOFT TISSUE FILLERS CURRENTLY EMPLOYED IN THE US	
Trade name (®,™)	**FDA-approved indication**
Hyaluronic acid	
Restylane, Restylane-L*	• moderate to severe facial wrinkles and folds • lip augmentation
Restylane Refyne* Restylane Defyne*	• moderate to severe facial wrinkles and folds • augmentation of the chin region (Defyne only)
Restylane Silk* Restylane Kysse*	• lip augmentation • correction of perioral rhytides
Restylane Lyft* (formerly Perlane-L)	• moderate to severe facial folds and wrinkles • age-related volume loss and augmentation of the midface • volumization of the dorsal hands
Restylane Contour*	• cheek augmentation
Juvéderm Ultra, Juvéderm Ultra XC*	• moderate to severe facial wrinkles and folds • lip and perioral augmentation
Juvéderm Ultra Plus, Juvéderm Ultra Plus XC*	• moderate to severe facial wrinkles and folds
Juvéderm Voluma XC*	• age-related volume loss in the midface • augmentation of chin region
Juvéderm Vobella XC*	• lip augmentation • correction of perioral rhytides
Juvéderm Vollure XC*	• moderate to severe facial wrinkles and folds
Juvéderm Volux XC*	• improving jawline definition
Belotero Balance, Belotero Balance + *	• moderate to severe facial wrinkles and folds
Resilient HA (RHA) 2, 3, 4*	• moderate to severe dynamic facial wrinkles and folds
RHA Redensity*	• moderate to severe dynamic perioral wrinkles
Synthetic†	
Polymethylmethacrylate microspheres plus bovine collagen (Bellafill)*	• correction of nasolabial folds • acne scars
Poly-L-lactic acid‡ (Sculptra and Sculptra Aesthetic)	• HIV-associated lipoatrophy • shallow-to-deep smile lines (nasolabial folds), contour deficiencies, and other facial wrinkles
Calcium hydroxylapatite‡ (Radiesse)	• HIV-associated lipoatrophy • moderate to severe facial wrinkles and folds • volumization of the dorsal hands
Calcium hydroxylapatite plus lidocaine (Radiesse +)*	• moderate to severe facial wrinkles and folds
Silicone	• none¶
Autologous	
Autologous fat	• not regulated as long as not modified in any way
Azficel-T (LAVIV)	• moderate to severe nasolabial fold wrinkles in adults

*Contains 0.3% lidocaine.
†Bellafill® contains bovine collagen.
‡Plus carboxymethyl-cellulose.
¶Silikon 1000 is FDA-approved for intraocular use.

Table 158.4 FDA-approved indications for soft tissue fillers currently employed in the US. In general, soft tissue fillers are approved for use in adults and not in the pediatric population. FDA, US Food and Drug Administration. For updates, see www.fda.gov.

Temple

Periosteal depots, deep to the superficial temporal vessels, are used to correct an atrophic temple. The needle is injected inside the "safe zone" whose border is 1 cm superior to the superior orbital rim, 1 cm lateral to the temporal fusion line, and 2.5 cm superior to the zygomatic arch where the middle temporal vein lies[17,18].

SOFT TISSUE AUGMENTATION: PREINJECTION CONSIDERATIONS
Medical background

• Medications (anticoagulants, antiplatelet agents)
• Medical history
  • Autoimmune connective tissue disease, e.g. systemic sclerosis
  • Granulomatous disorders, e.g. sarcoidosis
  • Scarring conditions (e.g. keloids) or tendency to form hypertrophic scars
  • Previous facial herpes simplex viral infection
  • Previous hypersensitivity reactions/allergies
• Pregnancy and lactation
• Surgical history, including cosmetic procedures
  • Rhytidectomy, blepharoplasty
  • Reconstructive surgery
  • Facial implants
  • Previous injections of soft tissue fillers and neurotoxins

Defect parameters
• Location • Volume required • Alternative and simultaneous treatments
Patient goals

• Defect of concern
• Expectations regarding
  • Degree of correction
  • Product longevity
• Recuperation time ("downtime")
• Risk/benefit ratio

Table 158.5 Soft tissue augmentation: preinjection considerations.

Lips

Injections should be superficial, as the labial arteries usually course more deeply between the mucosa and orbicularis oris at the wet–dry border[19].

Chin, Jawline

Because the facial artery crosses the mandible just anterior to the border of the masseter muscle, injections along the rami in this region must sit above the bone. Periosteal injection at the gonial angle appears to be safer when sharpening the contour and widening the jaw or the midline mandible to create anterior or inferior chin projection[20].

Consultation and Evaluation

With a firm knowledge of anatomy, injectors can then approach patient consultation and evaluation. Baseline asymmetry, subjective defects, and realistic expectations should be discussed with the patient (Table 158.5). To fully appreciate the depth and scope of the defect, patients should be placed in a gravity-dependent or seated position with adequate lighting. The latter should be at an acute angle in order to accentuate surface irregularities and deficits. A careful patient selection process will assist in determining ideal candidates for soft tissue augmentation. Contraindications include prior allergy to the filler material or its constituents (e.g. lidocaine). Pre-existing conditions in the planned treatment area such as dermatitis, acne, or infection may require postponement of the procedure. The expected level of improvement and longevity are also key discussion points.

Prior to the procedure, patients should be instructed to abstain from all *nonessential* medications that can inhibit coagulation and platelet aggregation. For example, aspirin is avoided for 10–14 days and NSAIDs for 5–7 days in order to decrease the risk of bleeding and bruising. In addition, omega-3 fatty acids, fish oil, and a number of over-the-counter supplements should be discontinued (see Table 133.3). Prior to the procedure, written consent is obtained and both make-up and cutaneous debris are removed[21]. Pre- and post-treatment photographs are strongly recommended.

Downloaded for Anonymous User (n/a) at Egyptian Knowledge Bank from ClinicalKey.com by Elsevier on March 10, 2024. For personal use only. No other uses without permission. Copyright ©2024. Elsevier Inc. All rights reserved.

Preparation

Clean technique is critical in preventing contamination during the initial handling, mixing, and injecting of the filler. The skin is cleansed with alcohol, chlorhexidine (avoiding the ear canal and eye), hypochlorous acid or other antimicrobial agent, and gloves are changed after intraoral manipulation. Percutaneous injections of fillers can be painful, necessitating the consideration of adding anesthesia to the treatment protocol. Although the physician can combine fillers with an anesthetic, most commercial products are now premixed with lidocaine (see Table 158.4). Some injectable products may require nerve blocks and/or regional anesthesia (see Ch. 143). More commonly, however, ice or topical anesthetic preparations are sufficient.

Injection Techniques

Proper placement of the filler material is crucial. Common injection techniques include serial puncture, linear threading, fanning, cross-hatching, and depot injection[22]. In the *serial puncture technique*, small amounts of filler are sequentially deposited along the wrinkle or fold. The injections are placed close to one another so that the filler can blend in a continuous fashion; post-injection massage can also help to blend the filler so that it is evenly distributed. Using the *linear threading technique*, the full length of the needle/cannula is inserted into the proper dermal or subcutaneous plane, and the filler is injected in a retrograde manner as the needle is withdrawn. Conversely, the material can be injected as the needle is advanced (anterograde), creating blunt dissection within the tissue space. The *fanning technique* involves multiple passes in different, but evenly spaced, directions without withdrawing the needle/cannula from its original site of insertion. The *cross-hatching* or *radial injection technique* involves evenly spaced, linear injections in a grid-like pattern; this technique is used for filling large areas and for the oral commissures[23]. Finally, *depot injections* are useful when placing volumizing fillers within the subcutaneous fat or along the periosteum. Occasionally, small depot aliquots are also placed along the infraorbital ridge, with a movement toward using cannulas in this region. Massage immediately after depot placement of filler helps to blend the product into the natural contour of the region.

Additional important recommendations[5]:

- *Inject small volumes slowly, under low pressure*. When there is arterial cannulation or compression from deposition adjacent to arteries, large volume, high pressure boluses may be more detrimental.
- *Retract the syringe plunger (reflux test) prior to injection*. If positive for blood, then intravascular placement is possible. Stop straight away and reposition. However, a negative reflux test does not exclude possible intravascular injection[15,24].
- *Continually move the needle or cannula tip to minimize the risk of prolonged intravascular injection of a larger bolus*.

Needles and Cannulas

Evolving consensus supports the use of blunt-tipped cannulas, especially those with a larger bore (e.g. 25 G)[25], to reduce the risk of vascular injury. Cadaveric and reflux studies suggest that larger diameter cannulas are less likely to perforate vasculature, when compared to smaller diameter cannulas (e.g. 27 G) or needles[14–16]. This is of particular importance in areas (e.g. cheeks, lips) where both needles and cannulas are FDA-approved. Blunt-tipped cannulas are best suited for injecting in the subdermal plane and are not appropriate for intradermal injections. One of the authors (DJ) demonstrates high-risk anatomy and the use of cannulas in Video 158.1.

INJECTABLE SOFT TISSUE FILLER MATERIALS

There is an ever-expanding array of fillers for soft tissue augmentation (see Table 158.4). Table 158.6 lists the characteristics of the ideal filler. While soft tissue fillers can be subdivided based upon derivation, depth of placement or duration of effect, most physicians develop preferences based upon location of desired augmentation.

Hyaluronic Acid Derivatives

Hyaluronic acid derivatives are currently the most commonly employed soft tissue fillers (Table 158.7). The term *hyaluronic acid* is derived from the Greek word for glass, *hyalos*, and is so named because of its clear appearance. Hyaluronic acid (HA) is a key glycosaminoglycan (GAG; previously referred to as mucopolysaccharides) within the extra-fibrillar matrix of the dermis (see Ch. 95). It is a ubiquitous component of connective tissue and is conserved amongst mammals, making it species-nonspecific. Within connective tissue, HA forms a gelatinous matrix that surrounds collagen and elastic fibers and creates volume via its water-binding capability. HA also plays a role in cellular migration and therefore it is important in the development and remodeling of tissues. A direct correlation exists between the amount of HA in the dermis and its water content as well as between HA content and the viscoelastic properties of the extracellular matrix. The concentration of naturally occurring HA within the skin decreases with age, resulting in a decreased ability to retain water, rendering the dermis less voluminous and increasing its propensity to wrinkle.

The HA molecule consists of a polysaccharide chain comprised of numerous repeating disaccharides of N-acetylglucosamine and D-glucuronic acid. The longer the chain, the higher the molecular weight. All currently available, FDA-approved HA fillers are derived from bacterial (*Streptococcus*) fermentation. "Raw" or non-crosslinked HA is supplied as a powder, forming a viscous liquid when exposed to water. If injected in this unmodified state, exogenous HA imparts a duration of correction of only 12 to 24 hours. In order to increase tissue residence time, HA molecules must be stabilized via chemical crosslinking of the polysaccharide chains; this modification slows enzymatic breakdown and provides an acceptable duration of correction. Most commercially available, FDA-approved HAs are crosslinked by BDDE (1,4-*b*uane*d*iol *d*iglycidyl *e*ther), with each filler differing in its manufacturing process.

Following the initial crosslinking, HA exists as a gel similar in consistency to Jell-O®. Subsequent post-crosslinking modifications, which vary depending upon the specific product, impart different attributes. For example, with the Restylane® family, the gelatin is passed through a sieve that creates microscopic particles of identical shape and size. Restylane® (approved in 2003) is then suspended in phosphate-buffered saline at a concentration of 20 mg/ml with 100 000 gel particles/ml. By comparison, Restylane® Lyft (formerly Perlane-L®) has a larger mean gel particle size with 10 000 particles/ml. Refyne, Defyne, Contour, and Kysse are more recent additions to the Restylane® family (see Table 158.4).

The Juvéderm® family relies on a proprietary technology that creates particles of random shapes and sizes. Juvéderm® products (first approved in 2006) have an HA concentration of 24 mg/ml, with Juvéderm® Ultra Plus being more heavily crosslinked than Juvéderm® Ultra (Fig. 158.1). Belotero Balance® is a monophasic, non-particulate gel crosslinked in two consecutive reactions, resulting in a cohesive HA

PARTIAL LIST OF THE CHARACTERISTICS OF THE IDEAL FILLER SUBSTANCE	
• FDA-approved • Non-allergenic (minimal risk of hypersensitivity, no pretesting required) • Non-carcinogenic and non-teratogenic • User-friendly product (e.g. easy flow, ergonomic syringe) • Versatile syringe volumes (e.g. touch-up syringes) • Easy storage (no need for refrigeration) • Long shelf-life	• Affordable • Long-lasting • Predictable level of correction • Painless • Minimal recuperation • Minimal adverse sequelae (e.g. infection, ecchymosis) • No migration • No overt cutaneous change (undetectable) • Correctable post-injection (e.g. with hyaluronidase)

Table 158.6 Partial list of the characteristics of the ideal filler substance. FDA, US Food and Drug Administration.

BENEFITS OF HYALURONIC ACID DERIVATIVES
• Identical in all species and all tissue types • Minimal risk of hypersensitivity reaction (no skin test required) • Room temperature storage • Biodegradable • Long-lasting and stable • High degree of safety (biocompatible, resorbable, reversible)

Table 158.7 Benefits of hyaluronic acid derivatives.

Downloaded for Anonymous User (n/a) at Egyptian Knowledge Bank from ClinicalKey.com by Elsevier on March 10, 2024. For personal use only. No other uses without permission. Copyright ©2024. Elsevier Inc. All rights reserved.

Fig. 158.1 Hyaluronic acid – volumization in a patient with lean body mass. A Pre-treatment. **B** One week following injection of large volumes of Juvéderm® Ultra Plus to the cheeks and Juvéderm® Ultra to the brow area, nasolabial folds, and oral commissures.

gel with varying zones of crosslinking density. The HA concentration in Belotero Balance® (approved in 2011) is 22.5 mg/ml.

The pivotal, phase III trials leading to FDA approval of Restylane®, Juvéderm®, and Belotero Balance® were six-month, randomized, blinded, multicenter, split-face, controlled trials (RCTs) that compared Zyplast® collagen to the respective HA for the treatment of moderate to severe nasolabial folds[26–28]. At six months, all three HA fillers demonstrated superiority over Zyplast® collagen, with inter-study design and results having more similarities than differences (Fig. 158.2A). The HA products have been shown to be safe in all skin types. Further studies, focusing on repeat treatment after six months, suggest that less volume is required to regain optimal correction[28–30]. Often, an extended duration of 1–2 years or more was observed (Fig. 158.2B).

For the treatment of moderate to severe wrinkles and folds, HA products are usually injected into the immediate subdermal plane or superficial subcutis. If injected too superficially into the dermis, contour irregularity as well as a bluish discoloration due to the Tyndall effect may occur. The latter results from the optical scatter of different wavelengths of light encountering a clear substance. Recent studies suggest that Belotero Balance®, if injected more superficially (intradermally), integrates more smoothly into the dermis as compared to the Restylane® and Juvéderm® families. The former is also less likely to create a Tyndall effect[31]. This makes Belotero Balance® particularly well suited for treatment of superficial, etched-in lines such as vertical lip lines (Fig. 158.3 & 158.4)[32]. Both Restylane® and Juvéderm® Ultra are FDA-approved for lip augmentation (Fig. 158.5), although Belotero Balance® is often used off-label for this indication[33].

In 2013, Juvéderm Voluma® XC ("Voluma") was the first HA filler to be FDA-approved for deep injection for cheek augmentation as a means of restoring age-related volume loss in the mid face (Video 158.2). This filler consists of a 20 mg/ml mixture of low- and high-molecular-weight HA. Voluma® differs from other HA fillers in that the lower-molecular-weight component, composed of shorter polysaccharide chains, allows for more efficient crosslinking (Vycross® technology). This, in turn, produces a highly cohesive gel with greater lift capability. Results from the pivotal phase III multicenter, single-blinded RCT showed significant improvement in moderate to severe, age-related midfacial volume loss at six months (compared to the no-treatment control group; Fig. 158.6). Data suggest that nearly half of the patients maintained correction up to 24 months, emphasizing its long-term effectiveness.

Reported adverse events with Voluma® were similar to other HA fillers and included swelling, tenderness and purpura, which resolved within a week in the majority of individuals[34]. Recent data have

Fig. 158.2 Correction of nasolabial folds. A Comparison of bovine collagen (Zyplast®) to hyaluronic acid (Juvéderm® Ultra Plus). **B** Demonstration of long-term effect with repeated injection of hyaluronic acid (Juvéderm®). *Adapted from Smith SR, Jones D, Thomas JA, et al. Duration of wrinkle correction following repeat treatment with Juvederm hyaluronic acid fillers. Arch Dermatol Res. 2010;302:757–62.*

Downloaded for Anonymous User (n/a) at Egyptian Knowledge Bank from ClinicalKey.com by Elsevier on March 10, 2024. For personal use only. No other uses without permission. Copyright ©2024. Elsevier Inc. All rights reserved.

Fig. 158.3 Treatment of superficial, etched-in lines with Belotero Balance®. **A** Pre-treatment. **B** Two weeks post-treatment.

Fig. 158.4 Treatment of superficial lines with Belotero Balance®. A Pre-treatment. **B** Two weeks post-treatment.

Fig. 158.5 Hyaluronic acid – lip and perioral augmentation. A Prior to injection of Restylane® into the perioral area. **B** Three months post-injection with correction maintained. *Courtesy Seth L. Matarasso, MD.*

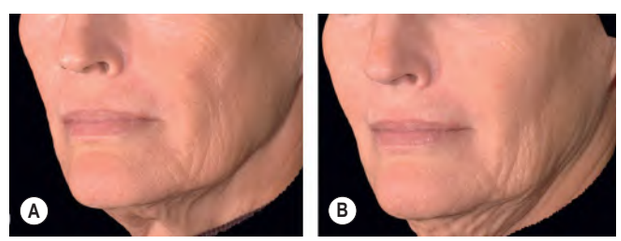

Fig. 158.6 Restoration of midface volume with Juvéderm Voluma® XC. **A** Pre-treatment. **B** Six months post-treatment. *From Jones D, Murphy DK. Volumizing hyaluronic acid filler for midface volume deficit: 2-year results from a pivotal single-blind randomized controlled study. Dermatol Surg. 2013;39:1602–12.*

pointed to an increased incidence of delayed adverse events (e.g. edema, nodules) in up to 1% of treated individuals. They occur months after injection, possibly due to the degradation process triggering an inflammatory response, either spontaneously or after an immunologic trigger[35]. Juvéderm Voluma® XC is intended for injection into deeper subcutaneous and periosteal planes and should not be injected intradermally; nor should it be injected into the lip or glabellar areas.

In 2016 and 2017, two additional fillers based upon Vycross® technology received FDA approval. Vobella XC® is indicated for lip augmentation and correction of perioral rhytides in adults over the age of 21 years, whereas Vollure XC® corrects moderate to severe wrinkles and folds such as the nasolabial fold (see Table 158.4). Unlike previously FDA-approved products with these indications, Vollure® is the first HA filler reported to last up to 18 months within the nasolabial folds in the pivotal trials.

The most recently introduced family of products in the US (approved in 2017 but distributed in 2020) is Resilient HA (RHA®). They contain 23 mg/ml and are produced with similar, but fewer modifications than other HA families. Double-blind RCTs of RHA® 2–4 had a primary six-month endpoint and were compared to control HA filler or no

Downloaded for Anonymous User (n/a) at Egyptian Knowledge Bank from ClinicalKey.com by Elsevier on March 10, 2024. For personal use only. No other uses without permission. Copyright ©2024. Elsevier Inc. All rights reserved.

treatment of nasolabial folds; based upon follow-up through 64 weeks, there was non-inferiority[36,37].

A unique feature of HA is its reversibility, and complications from HA fillers can often be easily corrected. Injections of hyaluronidase (Vitrase®, Hylenex®) can dissolve previously injected HA; this is very helpful if the filler has been misplaced, there is a complication post-injection (e.g. vascular occlusion, delayed granulomatous reaction), or there is impending vascular necrosis. An *in vitro*, dose-response study suggested that Juvéderm® was more resistant to hyaluronidase when compared to Restylane®. In the authors' experience, 10 units (U) of hyaluronidase (Vitrase®) per 0.1 cc of Juvéderm or 5 U per 0.1 cc of Restylane® may be the most appropriate dose to dissolve the HA[38]. Up to 30–40 U of Vitrase® may be required per 0.1 cc of Voluma®[39]. The need for the greater amount of hyaluronidase for correction of these products likely reflects their more highly crosslinked nature.

All currently FDA-approved HA families have a product that is pre-packaged admixed with lidocaine, which significantly reduces pain on injection (see Table 158.4).

Poly-L-Lactic Acid

Polymerized poly-L-lactic acid (PLLA; Sculptra®) augments soft tissue by stimulating the production of collagen. In 2004, it was FDA-approved for the correction of HIV-associated facial lipoatrophy. Five years later, the FDA approved Sculptra® Aesthetic for the correction of shallow-to-deep nasolabial fold contour deficiencies and other facial wrinkles. It is often injected off-label for panfacial rejuvenation in immunocompetent individuals with limited lipoatrophy, improvement of nonfacial skin laxity[40], and nonsurgical gluteal augmentation[41]. However, effects are often subtle with many treatments required for optimal results.

Sculptra® is powdered lyophilized suture material (Vicryl® [polyglactin 910]); the freeze-dried preparations of PLLA can be stored at room temperature. Based upon early study designs, the current aesthetic label recommends that each vial be reconstituted two hours prior to deep dermal injection with a total of 5 ml of liquid: 4 ml of sterile water and 1 ml of lidocaine. This results in a thick suspension of 4.45% PLLA. Refinements in protocol have led to the common off-label practice of a >24-hour hydration time with higher dilutions, e.g. addition of up to 9–11 ml of liquid (or higher for the body), to generate a more uniform suspension and reduce the risk of papule formation[42].

Immediately prior to injection, the mixture is vigorously agitated. A 25–26 G needle is used to place the filler in the subcutaneous plane and care is taken to avoid overcorrection. Intradermal injection can result in visible papules. Frequent needle changes may be necessary, as the material has a tendency to form clumps and clog the bore. There may be the appearance of some immediate augmentation from saline in the reconstituted solution and some edema. However, to achieve optimal correction and prolonged neocollagenesis, the recommended protocol is a series of three or more sessions at 3- to 6-week intervals. Persistence of augmentation varies, but some improvement can be seen for up to 1.5 to 2 years.

Palpable, but not visible, papulonodules develop in some patients, and a granulomatous reaction at sites of injection can also arise. All of these complications tend to persist for months to years before resolving. To try to minimize papule formation, the following can be done: use greater dilution volumes, increase the time interval between reconstitution and injection, avoid intradermal injection, inject smaller aliquots per site, and vigorously massage the injected areas to eliminate any lumpiness. In addition to massaging during and post-treatment, it is often recommended that the patient follow the "rule of 5 s": massage for 5 minutes 5 times daily for 5 days. That said, a small study found that this advice had no significant impact on nodule formation or treatment outcomes[43].

Calcium Hydroxylapatite

In 2006, Radiesse® was FDA approved for the correction of moderate to severe facial folds and wrinkles (e.g. nasolabial folds) and for the correction of signs of HIV-associated lipoatrophy. Correction of volume loss of the dorsal hands was a later indication, receiving FDA approval in 2015[44]. It is safe in all skin types (Fig. 158.7)[42,45,46]. Radiesse® is a milky white suspension comprised of two components: (1) an aqueous gel carrier containing glycerin, sodium carboxymethylcellulose, and water; and (2) 25–45 micron microsphere particles of calcium hydroxylapatite (CaH). CaH is a non-allergenic (inert) bioceramic that is identical to the primary mineral constituents found in bone and teeth. This biocompatible product contains no human, bacterial, or animal products and poses minimal risk for hypersensitivity reactions. Utilization of the product was initially limited due to the significant discomfort and throbbing after injection, so the FDA approved the practice of pre-mixing Radiesse® with 2% lidocaine immediately prior to injection. Subsequently, a lidocaine-containing version, Radiesse® (+), became available. The material is deposited deeply at the dermal–subcutaneous junction. Injection provides immediate results, and no overcorrection or undercorrection is required[1].

As the gel carrier correction gradually resolves, it is replaced by new collagen formation stimulated by the scaffold of calcium hydroxylapatite particles. While histologic studies have demonstrated the presence of CaH and neocollagenesis for up to 78 weeks, the duration of clinical correction has not been well documented beyond 12 months[1]. Lip augmentation is contraindicated, as mucosal granulomas may form and the constant motion of the lip and compression from contraction of the orbicularis oris may cause migration and clumping of the filler (Fig. 158.8)[47]. Off-label uses of this product include revolumizing the face of immunocompetent individuals[1,47] as well as improving skin laxity via biostimulation with dilute and hyperdilute mixtures injected over repeated sessions[48].

Since Radiesse® is radio-opaque, the patient should be informed that it may be visible on radiographs as well as CT scans. However, there is no evidence that calcium hydroxylapatite particles obscure underlying structures or mask abnormal pathology[49].

Lipotransfer

Historically, autologous fat has always been considered one of the safest fillers, with estimates of success as high as 70%, but two concerns have remained. The original *en bloc* technique required excision of the donor tissue and a resultant second defect; essentially, patients traded one

Fig. 158.7 Treatment of age-related facial lipoatrophy with Radiesse®.
A Pre-treatment. **B** Post-treatment (2 weeks).

Downloaded for Anonymous User (n/a) at Egyptian Knowledge Bank from ClinicalKey.com by Elsevier on March 10, 2024. For personal use only. No other uses without permission. Copyright ©2024. Elsevier Inc. All rights reserved.

Fig. 158.8 Formation of papules and nodules due to placement of Radiesse® into the lip. A, B The size can vary from a few millimeters to over a centimeter. *A, Courtesy Seth L. Matarasso, MD.*

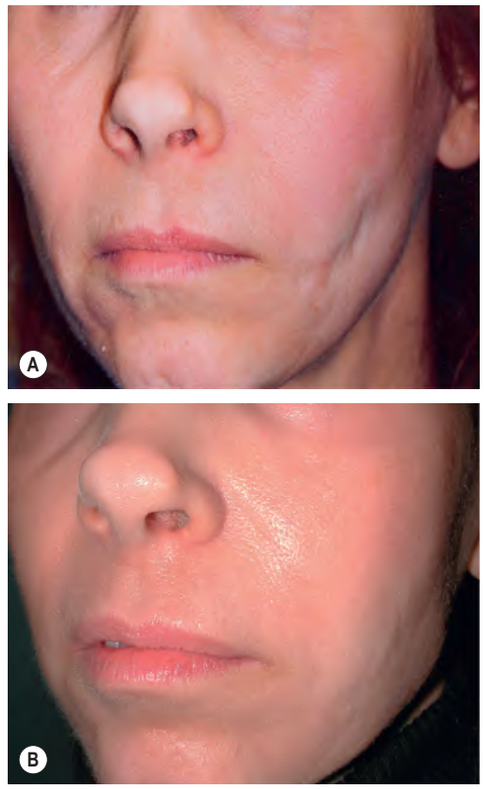

Fig. 158.9 Lipotransfer and subcision to correct scarring due to previous surgical excision of a cyst. A Pre-treatment. **B** Post-treatment.

defect for another. Furthermore, the non-particulate solid nature of the tissue required implantation, with the potential for incisional scars. The arrival of tumescent liposuction in the 1980s solved many of these existing problems. A by-product of liposuction, the suctioned fat was easily accessible and could be reinjected through small cannulas/needles, leading to a resurgence of autologous fat grafting (AFG).

Areas amenable to AFG include the nasolabial folds, cheeks, infraorbital region, marionette lines, and lips. Scars as well as stable disease processes associated with idiopathic facial subcutaneous atrophy (e.g. linear morphea, Parry–Romberg syndrome) can also benefit (Fig. 158.9). The dorsal hands often share all of the signs of aging found in sun-exposed areas, and replacing fat in the dorsal hands masks the appearance of protruding tendons and blood vessels, imparting a more youthful appearance. Adipose transfer has also been shown to be effective in treating HIV-associated lipoatrophy in patients who have a suitable donor reserve.

There is great variability in the techniques used to procure, purify, and inject adipose tissue, resulting in great variability in outcomes. Table 158.8 reviews basic concepts, but a detailed discussion of the evolving nuances is beyond the scope of this chapter.

Silicone

Silicone (polydimethylsiloxane) consists of repeating units of dimethylsiloxane terminated with trimethylsiloxane. Centistoke (cs) refers to the viscosity of silicone oil and is directly related to the chain length of the repeating units. A 1 cs product is equivalent in consistency to water, a 350 cs product is similar in consistency to mineral oil, and a 1000 cs product is similar in texture to honey. While silicone has had a tumultuous history and continues to be controversial, it has largely been replaced by HA, PLLA, and CaH fillers.

Medical grade (350 cs) liquid silicone was never approved by the FDA for injection into humans and such use remains prohibited in the US. However, there is an FDA indication for AdatoSil® (5000 cs; approved in 1994) and Silikon® (1000 cs; approved in 1997) which is intraocular injection to produce tamponade to treat retinal detachment. Under the US FDA Modernization Act of 1997, physicians gained the right to use medical devices in an off-label manner, so after years of being banned for cosmetic implantation, physicians could legally use these FDA-approved and standardized silicone oils.

Silikon® 1000 is the most appropriate form of injectable liquid silicone currently available for off-label soft tissue augmentation. It is injected in a microdroplet, serial puncture method, most often for severe HIV-associated lipoatrophy (Fig. 158.10). As placement of the product results in permanent augmentation, there is very little margin

LIPOTRANSFER
Advantages
• Biocompatibility with avoidance of allergy • Abundant graft supply • Three-dimensional volumization • Potential long-standing correction
Disadvantages
• Need for donor fat harvesting • Percentage of graft that survives is unpredictable • Inability to remove after placement • Requires a two-step procedure: harvesting and insertion of the fat • Significant "downtime", e.g. post-procedural edema • Rare risk of fat emboli and vision changes including blindness
Key components of procedure

• Anesthesia – general or local tumescent (see Ch. 143)
• Fat harvesting
  • From easy-to-access areas that are relatively insensitive to dietary fluctuation – upper outer buttock/flank, medial knee
  • Donor fat aspirated with a 12–14 G, single-holed microcannula mounted on a conventional hypodermic (10–20 ml) Luer-Lok® syringe or by traditional liposuction methods (see Ch. 156)
  • Processing via different methods (e.g. sterile saline washing; centrifugation to separate excess fluid, erythrocytes, and nonviable cells; use of an FDA-cleared filtration system such as PUREGRAFT)
  • Limited postoperative morbidity
• Fat re-injection
  • Processed, pure supernatant injected into subcutaneous plane using a large-bore (16–18 G) cannula/needle
  • Great variability in technique – multiple passes with layering of small fat droplets, intramuscular placement, superficial nanofat*
  • Repeat smaller volume injections over time have greater viability than a single large implantation; passive diffusion within the recipient bed cannot sustain the latter
  • Massage to disperse and contour
• Postoperative care
  • Systemic antibiotics
  • Pain management, avoiding aspirin-containing products

*Nanofat is highly emulsified and the adipocytes are mechanically disrupted such that there are no viable cells; the injection contains adipose-derived stem cells and growth factors.

Table 158.8 Key features of lipotransfer[7,50–56].

Downloaded for Anonymous User (n/a) at Egyptian Knowledge Bank from ClinicalKey.com by Elsevier on March 10, 2024. For personal use only. No other uses without permission. Copyright ©2024. Elsevier Inc. All rights reserved.

Fig. 158.10 Correction of HIV lipoatrophy with injectable silicone (Silikon® [1000 cs]). **A** Pre-treatment. **B** Five years post-treatment.

for error, and experience plus meticulous technique are essential. Since HIV-associated facial volume loss has become less common and there are safer alternative fillers with excellent outcomes, it is the authors' opinion that even when expertly injected, the incidence of adverse events is too high to justify its continued use. These complications include facial edema, overcorrection, superficial beading, movement of the product to a distant site (drift)[57,58], and granulomatous or inflammatory reactions with delayed firmness and nodules. In a 10-year retrospective follow-up of patients treated for HIV-associated facial lipoatrophy, adverse events were observed in 7%[58].

Polymethylmethacrylate (PMMA) Microspheres

Bellafill® (formerly Artefill®) is the only FDA-approved soft tissue filler that is a non-resorbable implant. It is indicated for the correction of nasolabial folds and acne scars. Polymethylmethacrylate (PMMA) microspheres are suspended in a solution of 3.5% bovine collagen and 0.3% lidocaine; the collagen serves as a carrier and is degraded within 1–3 months following injection. As a result, Bellafill® is currently the only commercially available filler in the US that requires skin testing for bovine collagen hypersensitivity. The remaining intact, inert, non-biodegradable 30–40 micron PMMA beads, similar to Lucite™ or Plexiglas™, are large enough to avoid phagocytosis but small enough to promote permanent augmentation. Once the host's collagen has encapsulated the microspheres, the augmentation has been purported to be permanent[42,59].

Bellafill® is a third-generation product whose predecessors were Arteplast® and Artecoll®. Improvements include PMMA particles that are more uniform in size and rounder with a smoother surface. Microspheres <20 microns, which were responsible for a high incidence of granuloma formation in previous generations, have been removed. However, even with this newer formulation which has a higher safety profile[59], there continues to be a risk of disfiguring delayed granulomas. The latter occur more commonly with off-label use[60], and in our experience, inevitably recur and never fully resolve. While the results may be permanent and therefore more economical, so are any adverse effects, which may require serial treatment with intralesional injections of 5-fluorouracil plus triamcinolone, oral antibiotics, or surgical excision[61].

PLATELET-RICH PLASMA

Platelet-rich plasma (PRP), an autologous solution with a high concentration of platelets and fibrin in a small volume of plasma, may be used to enhance one's complexion and less often as an injectable filler. Given the high number of growth factors implicated in extracellular matrix remodeling that it contains, PRP has become an increasingly popular option for rejuvenation. While the quality of published studies has appeared to lag behind quantity, there is a growing number of small RCTs, albeit with different designs, that have reported benefit from intralesional PRP.

One split-face, randomized, rater-blinded study of 20 Asian patients found good to moderate improvement in lower eyelid wrinkles and skin tone after three injection sessions (compared to saline control)[62]. One month after a single PRP session, an 89% increase in collagen density was observed histologically compared to baseline and 93% more collagen induction compared to the saline control injections[63]. However, the latter also led to improvement, possibly due to a needling effect. In another study of a single session of PRP versus saline in which photographs were reviewed at six months, masked subjects, but not two expert dermatologists, saw significantly better fine and coarse skin texture[64]. The authors argued that this discrepancy may stem from the failure of imaging to detect nuanced changes and patients' intimate understanding of their own skin topography. A more recent three-session, saline-controlled trial found statistically significant improvement in wrinkles, texture, and pores using a VISIA® system[65]; the latter may better detect subtle changes in the skin canvas than does global photography. An *in vitro* arm of this trial demonstrated that PRP mitigated ultraviolet B-induced matrix metalloproteinase-1 and tyrosinase upregulation and induced fibrillin and tropoelastin (precursor to elastin) expression. Perhaps this may explain the effects of PRP on skin photoaging and its enhancement of visible complexion metrics. Histologic improvement of solar elastosis following PRP injections has also been reported[66].

Taken together, these results support a potential role for PRP in improving skin texture, softening fine lines, and ameliorating degenerative soft tissue changes. While meaningful changes may be seen with a single treatment, more robust aesthetic outcomes seem to come from a series of sessions. However, the studies to date remain small, with a wide variation in protocols and outcome measures, many of which are subjective. There is a need for rigorous, larger scale RCTs to better standardize therapy[67]. Lastly, the combination of PRP plus HA fillers and platelet-rich fibrin matrix (derived from a true clot but often misclassified in the literature) should be investigated for any synergistic biostimulatory activity.

COMPLICATIONS

The popularity of soft tissue fillers is in part due to their favorable side-effect profile. Common injection-related phenomena include erythema, swelling, pain, and bruising. These generally resolve within a week without treatment. The erythema and swelling often appear immediately after injection. Minimizing the number of skin punctures and applying ice may reduce pain, erythema, and swelling[68]. To limit bruising, patients should be instructed to abstain from medications that inhibit platelet aggregation for at least 7–10 days prior to injection. Vigorous exercise with its associated blood pressure elevation should also be avoided for the first 24 hours after the injections. The use of a small-gauge needle, slow injection technique with small aliquots of product as well as blunt cannulas and fewer puncture sites may further minimize bruising. However, bruises are often inevitable and treatment with intense pulsed light or pulsed dye and potassium titanyl phosphate (KTP) lasers may be effective therapies, as they all can target the hemoglobin chromophore contained in the extravasated blood[69]. Superficial bruising from fillers often lightens substantially within a day following laser- or light-based treatment.

More serious complications from soft tissue fillers may occur and include: (1) nodules, beading, and Tyndall effect from superficial placement; (2) infection; (3) hypersensitivity reactions; (4) delayed nodule formation; and (5) vascular compromise (Fig. 158.11A; Table 158.9). Inappropriate placement of fillers may result in the development of papulonodules, which are palpable and often visible. Injecting too superficially with an HA filler may lead to beading as well as blue–gray discoloration due to the Tyndall effect. Hyaluronidase

Downloaded for Anonymous User (n/a) at Egyptian Knowledge Bank from ClinicalKey.com by Elsevier on March 10, 2024. For personal use only. No other uses without permission. Copyright ©2024. Elsevier Inc. All rights reserved.

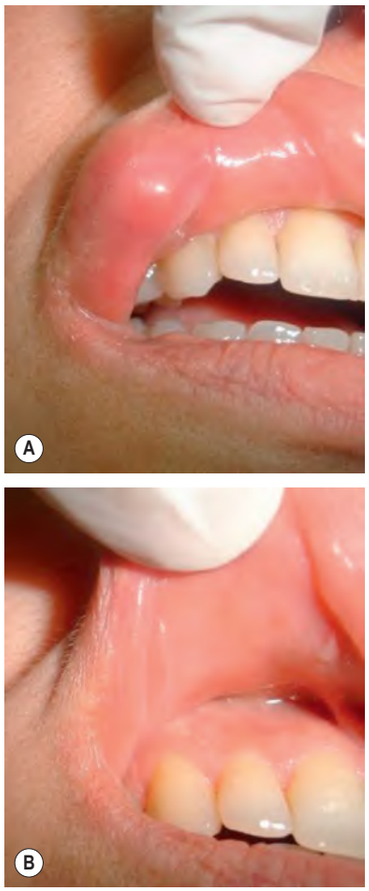

Fig. 158.11 Foreign body reaction to hyaluronic acid. A Nodule due to granulomatous inflammation arose six weeks after injection. **B** Resolution following intralesional hyaluronidase and triamcinolone. *Courtesy Mahmoud Abdallah, MD.*

can be used to treat these complications (see above; Fig. 158.11B). Vitrase® and Hylenex® are the two FDA-approved formulations of hyaluronidase that may be used off-label for dissolving unwanted previously injected HA. Hylenex® is a genetically engineered human recombinant hyaluronidase, whereas Vitrase® is ovine testicle-derived hyaluronidase. In the ophthalmologic literature, the reported incidence of allergic reactions to hyaluronidase is ~1 in 2000. While to date no cases of allergy or anaphylaxis have been reported in the dermatologic literature, a preliminary intradermal skin test with a few units can be considered to exclude hypersensitivity. Because there is a theoretical risk of cross-reactivity in patients who are allergic to honeybees and yellow jackets, patients who have had severe reactions or anaphylaxis to bee stings should be skin tested prior to treatment[70]. Persistent papules can also occur following injection of PMMA microspheres, poly-L-lactic acid, and silicone. Methods to reduce this complication are outlined in Table 158.9.

Any time there is a breach in the integrity of the skin, infection can occur. To minimize the risk, the skin should be cleansed with an antimicrobial agent such as isopropyl alcohol, chlorhexidine (avoiding the ear canal and eye), or hypochlorous acid prior to injection. Patients with an infection may present with tender erythematous fluctuant nodules or abscesses. These skin findings may be accompanied by systemic symptoms such as fever. When an infection is suspected, a microbiological culture of exudate, if present, should be obtained and/or the lesion biopsied for histopathologic examination and tissue culture. Therapeutic interventions include incision and drainage and empiric broad-spectrum antibiotics such as dual therapy with a macrolide (e.g. clarithromycin) and quinolone until the culture results are available[5,71]. Trauma from injections may also trigger a recurrence of herpes simplex viral infection. Prophylactic antiviral treatment (e.g. valacyclovir) should be considered if a patient has a history of a post-procedure recurrence and when treating the perioral area in a patient with a history of recurrent herpes labialis[69].

Prior to the introduction of HA fillers, hypersensitivity reactions were more commonly observed (see above). There are a few reported cases of hypersensitivity reactions to HA (Fig. 158.12), and these may be due to residual proteins or impurities from the manufacturing process or they may be due to low-molecular-weight HA fragments[71]. Hypersensitivity reactions to HA fillers often resolve spontaneously after several months, but resolution may be accelerated by application of tacrolimus ointment, intralesional corticosteroids, intralesional hyaluronidase, and/or incision and drainage[68].

Delayed nodules are variable in their etiology and difficult to precisely diagnose without histopathologic and/or culture results. They may be secondary to a hypersensitivity reaction, soft tissue infection, development of a biofilm, or formation of a foreign body granuloma (see Table 158.9). Although delayed nodules occur more commonly with permanent fillers such as PMMA or silicone (hence our recommendation to avoid their routine use), they can develop following injection of temporary fillers including HA. Hypothetically, delayed nodules secondary to an *immune reaction* may be triggered by residual proteins in the product or, in the case of HA fillers, by low-molecular-weight fragments of HA[71]. As noted above, these fragments provide a theoretical explanation for the increased incidence of delayed reactions (~1%–4%) seen with the Vycross® fillers, which consist of a mixture of both high- and low-molecular-weight HA[34,72–75].

There are some data to suggest a greater risk of delayed reactions after influenza-like illnesses, following vaccinations, and during cold and flu season[72,76,77]. More recently, delayed filler reactions have been observed following administration of SARS-CoV-2 mRNA vaccines. These reactions were typically mild to moderate and resolved within a few days, often without treatment. In a case series, the ACE (angiotensin-converting enzyme) inhibitor lisinopril at a dose of 5–10 mg daily led to a rapid reduction in edema[78].

Biofilms may also cause delayed nodules. When filler is injected, it can become coated with colonies of bacteria that secrete a protective and adhesive matrix. This results in a low-grade chronic infection resistant to antibiotics and the immune system. Often bacterial cultures will be negative as standard culturing techniques are not sensitive enough to detect this type of infection. Delayed nodules due to formation of biofilms can present as a "sterile" inflammatory nodule, an abscess or other form of soft tissue infection, or a foreign body granuloma[71]. In order to try to prevent biofilm formation, it is important to cleanse the skin with an antimicrobial agent (e.g. chlorhexidine [avoiding the ear canal and eye]) prior to injection. Infectious delayed nodules may be related to biofilms, but can also be due to less common organisms such as atypical mycobacteria.

As all synthetic fillers represent foreign bodies, an intense host response can occur resulting in the formation of *foreign body granulomas*. Although infrequent, this presentation is more common with permanent fillers and has been well documented histologically (see Fig. 94.11)[79].

While there are several therapeutic interventions for delayed nodules (see Table 158.9), they should be guided by clinical judgment (e.g. inflammatory versus non-inflammatory, sterile versus infected) as well as culture results and/or histopathologic findings when available. Treatment options for removal of as much of the filler as possible include intralesional hyaluronidase (if an HA filler), incision and drainage, and excision. Delayed nodules are often immune-mediated and can be treated with a 1- to 2-week course of oral corticosteroids (e.g. prednisone 30 mg daily). If there is concern regarding an active infection, empiric oral antibiotics are advisable (see above)[5]. Additional therapies employed for delayed nodules include topical or intralesional corticosteroids, oral immunosuppressants, and lasers (see Table 158.9)[80].

While the majority of adverse events are reversible, vascular complications can be devastating and often irreversible (Table 158.10). Tissue necrosis may occur if filler is injected directly into the vasculature, resulting in ischemic or embolic phenomena. Of particular concern are the arteries in the mid central face that connect to the ophthalmic circulation, i.e. where the facial artery continues as the angular artery immediately superior to the nasolabial fold (see above). The angular artery then branches into the lateral nasal artery and other collateral vessels, which connect the internal and external carotid artery systems[95] (see Fig. 142.15).

Signs and symptoms of vascular compromise include pain, arborizing blanching, duskiness, and reticulated erythema that may extend along the artery and its branches (Fig. 158.13). Over time, this can progress to a necrotic eschar, ulceration, and scarring. Treatment should be instituted immediately at the first sign of vascular compromise[68]. If blanching occurs while injecting, immediately discontinue[5]. If the complication occurs with an HA filler, injection of hyaluronidase is recommended.

Downloaded for Anonymous User (n/a) at Egyptian Knowledge Bank from ClinicalKey.com by Elsevier on March 10, 2024. For personal use only. No other uses without permission. Copyright ©2024. Elsevier Inc. All rights reserved.

COMPLICATIONS FROM SOFT TISSUE FILLERS	
Complication	**Prevention and management strategies**
• Injection site reactions (erythema, swelling, pain, bruising)	• Avoid anticoagulants and antiplatelet agents such as aspirin • Consider cannulas to minimize bruising • Smaller needles may reduce pain and bruising • Ice application for swelling and pain • Intense pulsed light or vascular lasers can be used to treat bruising
• Nodules, beading, and Tyndall effect	• Avoid superficial placement; inject smoothly • Treat with massage, hyaluronidase (if HA filler), or aspiration/excision
• Persistent papules	• More common with certain products • For Bellafill®, inject smoothly • For Sculptra®, greater volume dilution • For silicone, use microdroplet technique
• Infection	• Pre-cleanse the skin with an antimicrobial agent, e.g. chlorhexidine* • Consider incision and drainage and/or antibiotics if infection occurs
• Herpes simplex virus reactivation	• Treat with oral antiviral medication if: (1) history of post-procedure reactivation; (2) injecting the perioral area in a patient with a positive history of herpes labialis; or (3) evidence of active outbreak
• Hypersensitivity†	• Avoid injection in patients with known sensitivity • Skin test for bovine collagen in the case of Bellafill® • Hypersensitivity after HA fillers often resolves spontaneously, but consider treatment with tacrolimus ointment, intralesional corticosteroids, intralesional hyaluronidase, and/or incision and drainage

• Delayed nodules:
  • Inflammatory/immune-mediated (hypersensitivity)
  • Biofilm-related
  • Infectious
  • Foreign body granuloma
	• Pre-cleanse the skin with an antimicrobial agent prior to injection, e.g. chlorhexidine*
	• Incision and drainage plus culture and/or biopsy for histopathologic examination
	• Hyaluronidase (if HA filler) or surgical excision
	• Oral broad-spectrum antibiotics for 2–6 weeks, e.g. clarithromycin, minocycline
	• For non-infectious etiologies, consider topical, oral or intralesional corticosteroids; intralesional 5-fluorouracil; oral immunosuppressants; or laser therapy

• Vascular compromise (necrosis, blindness)	• Injectors should have a thorough knowledge of facial vascular anatomy and the depth at which a filler should be placed • Aspirate before injecting • Use a cannula or smaller gauge needle in high-risk areas • Inject product slowly and in small aliquots; use low pressure to prevent retrograde injection • Discontinue the injection immediately if blanching occurs or if the patient complains of significant pain or vision changes • If vascular compromise of the skin occurs, begin warm compresses, massage, and oral aspirin; if HA filler, inject hyaluronidase along artery and its branches (for additional measures, see Table 158.10) • If blindness or visual compromise occurs, see protocol in Table 158.10

*Avoid the ear canal and eye.
†Dermal perivascular and periappendageal mononuclear infiltrate, with infiltration of the implanted filler by neutrophils, lymphocytes, histiocytes, and eosinophils.

Table 158.9 Complications from soft tissue fillers. HA, hyaluronic acid.

Different formulations of hyaluronidase are available, which makes it difficult to establish standardized dosing. Variable doses have been reported in the literature, from 10–30 units per $2 \times 2\,cm^2$ area along the artery and its branches[96] up to a total of 1500 units injected within the affected region[97]. Larger doses may be required for higher cross-linked fillers such as Voluma®[38]. As outlined in Tables 158.9 and 158.10, additional conservative measures can also be initiated. A thorough assessment and detailed treatment plan should be instituted for each patient. Immediate and ongoing care with frequent monitoring ensures optimal outcomes and decreases the risk of permanent complications[89].

Although very rare, more serious complications can occur secondary to *embolism* of the filler into the ocular circulation, leading to blindness and/or ophthalmoplegia, or into the brain, causing a cerebrovascular accident. Blindness may occur when there is sufficient pressure and retrograde arterial displacement of injected material from the peripheral vessels into the ocular circulation[98].

The anatomic sites most commonly associated with visual complications include the nose, glabella, forehead, and nasolabial fold[99], with the first three sites accounting for 85% of reported cases in a recent review. Here, the filler can travel through the branches of the internal carotid system (e.g. supratrochlear, supraorbital, dorsal nasal artery) to the ophthalmic artery, which further branches into the retinal artery. Alternatively, at sites such as the nasolabial fold, the filler can enter the ocular circulation via rich anastomoses between the external and internal carotid systems (see Ch. 142).

Fig. 158.12 Pustular and granulomatous reaction to injections of hyaluronic acid (Restylane®). *Courtesy Julie V. Schaffer, MD.*

Downloaded for Anonymous User (n/a) at Egyptian Knowledge Bank from ClinicalKey.com by Elsevier on March 10, 2024. For personal use only. No other uses without permission. Copyright ©2024. Elsevier Inc. All rights reserved.

MANAGEMENT OF SUSPECT VASCULAR OCCLUSION/INJURY WITH OR WITHOUT VISUAL COMPROMISE FOLLOWING INJECTION OF FILLER
Hyaluronic acid filler with blindness or visual compromise – time is crucial
• Halt injection at first signs of visual compromise, usually occurring unilaterally during or immediately post injection

• *Prior* to intervention, evaluate and document visual status in each eye independently including:
  • ability to read letters (Snellen chart, near card, magazine print)
  • ability to count fingers
  • ability to perceive hand motion
  • presence of light perception
  • extraocular muscle function
  • pupillary light response
• Photograph face in frontal position

• Immediately contact an ophthalmologist familiar with management of such cases   • As swift care is crucial and to avoid a delay in care, highly recommend establishing a pre-existing relationship and plan with an oculoplastic surgeon, ophthalmologist, and/or retina specialist
• Prompt hyaluronidase injections with >150 units into the treated region, ischemic skin, and along arterial paths leading to the eye • Consider injecting similar doses at the supraorbital and supratrochlear foramina • Repeat in quick succession as needed
• Retrobulbar and peribulbar hyaluronidase injections may be beneficial, but remain controversial

• Additional conservative measures:
  • Breathing into a paper bag to increase CO_2
  • Ocular massage with firm manual pressure to globe for 5–15 seconds alternating with rapid release for a total of 5 minutes; wait a few minutes, then repeat. Cyclical pressure inducing rapid reperfusion may dislodge embolus
  • Topical timolol (0.5%) and oral acetazolamide (500 mg) may decrease intraocular pressure

Hyaluronic acid filler with blindness or visual compromise and CNS involvement
• If signs or symptoms of CNS involvement, contact 911 and your local emergency stroke services • If no overt signs or symptoms, always evaluate for CNS involvement after addressing visual compromise
Hyaluronic acid filler without blindness/visual compromise
• Halt injection if "flash" in the syringe (vascular regurgitation) or tissue blanching or reticulation in treatment area (Fig. 158.13)

• Prompt high-dose hyaluronidase injection into skin at occlusion site as well as peripheral regions
  • Unanimously supported intervention[81–91], but optimal dosing unclear and based on anatomic region and product
  • Hundreds of units, perhaps pulsed in 15-minute intervals (500 units in increments of 125 units superior to single bolus)[92]

• Additional conservative measures:
  • Skin massage
  • Intralesional or systemic corticosteroids
  • Warm compresses
  • Oral aspirin
  • Nitroglycerin less beneficial
  • Hyperbaric oxygen for wound healing

Calcium hydroxylapatite
• Preliminary evidence of filler dissolution with sodium thiosulfate injection (0.1–0.2 ml of 250 mg/ml)[93,94], but its use for vascular occlusion remains unknown

Table 158.10 Management of suspect vascular occlusion/injury with or without visual compromise following injection of filler. Recommendations adapted from evidence-based guidelines from the American Society for Dermatologic Surgery (ASDS) Task Force[5]. Of note, there is no current standard of care for managing iatrogenic retinal embolism from hyaluronic acid filler (conditional recommendations, low certainty evidence). For vascular occlusion *sans* ocular event, the recommendations are strong with more moderate certainty evidence. CNS, central nervous system.

Fig. 158.13 Evolving vascular occlusion following injection of Juvéderm® Ultra XC into the cheek. Note the arborizing blanching, duskiness, and reticulated erythema that is observed in addition to pain.

The signature feature of ocular embolism is immediate visual impairment, which may be accompanied by ocular pain, nausea, and vomiting. Such events represent an ophthalmologic emergency. If any of these signs or symptoms occur, the patient should be sent urgently for ophthalmologic consultation, since treatment aimed at recanalizing the affected vessel(s) and restoring tissue perfusion needs to be performed within a short window of time. The most frequently cited interval is 90 minutes, but more recent investigations have suggested an interval as short as 10–15 min[100]. Therefore, a predetermined and detailed action plan is required. In an attempt to restore vision, prebulbar and retrobulbar injections of hyaluronidase can be performed immediately[7], but this intervention remains controversial (see Table 159.10)[101–103]. Because treatment of embolic blindness is usually unsuccessful, prevention is of critical importance[98].

When performed with care, soft tissue augmentation is a highly effective and safe procedure. To ensure the best outcomes while minimizing any adverse events, a thorough understanding of facial anatomy as well as proper injection technique are imperative. Injectors should be aware of both prevention and management strategies to minimize complications and improve patient outcomes (see Tables 158.9 and 158.10).

CONCLUSION

The vast array of available filler products, and those that are on the horizon, are only one means to improve tissue loss associated with aging and trauma. The optimal result may be best achieved by combining fillers of different depth, origin, and durability with other aesthetic procedures. The science of soft tissue augmentation is continuously evolving. Keeping abreast of advances and perfecting a few techniques will be most advantageous for patients; it is not only what is injected, but how it is injected, that determines the degree of success. Finally, regardless of the treatment chosen, it is the combination of clinical judgment, realistic expectations, meticulous preparation, and surgical skill that provides optimal results.

Copyright notice

Derek H. Jones retains copyright to his original photographs in Chapter 158.

Additional figures available in our eBook (see inside front cover for access code).

Downloaded for Anonymous User (n/a) at Egyptian Knowledge Bank from ClinicalKey.com by Elsevier on March 10, 2024. For personal use only. No other uses without permission. Copyright ©2024. Elsevier Inc. All rights reserved.

REFERENCES

1. Moers-Carpi M, Storck R, Howell D, et al. Physician and patient satisfaction after use of calcium hydroxylapatite for cheek augmentation. *Dermatol Surg*. 2012;38:1217–1222.
2. Ashinoff R. Overview: soft tissue augmentation. *Clin Plast Surg*. 2000;27:479–487.
3. Moody BR, Sengelmann RD. Topical tacrolimus in the treatment of bovine collagen hypersensitivity. *Dermatol Surg*. 2001;27:789–791.
4. Narins RS, Brandt FS, Lorenc ZP, et al. Twelve-month persistency of a novel ribose-cross-linked collagen dermal filler. *Dermatol Surg*. 2008;34(Suppl. 1):S31–S39.
5. Jones D, Fitzgerald R, Cox SE, et al. Preventing and treating adverse events of injectable fillers: evidence-based recommendations from the American Society for Dermatologic Surgery Multidisciplinary Task Force. *Dermatol Surg*. 2021;47:214–226.
6. Beleznay K, Carruthers JDA, Humphrey S, et al. Update on avoiding and treating blindness from fillers: a recent review of the world literature. *Aesthet Surg J*. 2019;39:662–674.
7. Beleznay K, Carruthers JDA, Humphrey S, Jones D. Avoiding and treating blindness from fillers: a review of the world literature. *Dermatol Surg*. 2015;41:1097–1117.
8. Kim Y-S, Choi D-Y, Gil Y-C, et al. The anatomical origin and course of the angular artery regarding its clinical implications. *Dermatol Surg*. 2014;40:1070–1076.
9. Choi D, Bae J, Youn K, et al. Topography of the dorsal nasal artery and its clinical implications for augmentation of the dorsum of the nose. *J Cosmet Dermatol*. 2018;17:637–642.
10. Lee W, Kim JS, Oh W, et al. Nasal dorsum augmentation using soft tissue filler injection. *J Cosmet Dermatol*. 2019;18:1245–1260.
11. Cho KH, Dalla Pozza E, Toth G, et al. Pathophysiology study of filler-induced blindness. *Aesthet Surg J*. 2019;39:96–106.
12. Cotofana S, Alfertshofer M, Frank K, et al. Relationship between vertical glabellar lines and the supratrochlear and supraorbital arteries. *Aesthet Surg J*. 2020;40:1341–1348.
13. Goodman GJ, Roberts S, Callan P. Experience and management of intravascular injection with facial fillers: results of a multinational survey of experienced injectors. *Aesth Plast Surg*. 2016;40:549–555.
14. Pavicic T, Webb KL, Frank K, Gotkin RH, et al. Arterial wall penetration forces in needles versus cannulas. *Plast Reconstr Surg*. 2019;143:504e–512e.
15. Tseng FW, Bommareddy K, Frank K, et al. Descriptive analysis of 213 positive blood aspiration cases when injecting facial soft tissue fillers. *Aesthet Surg J*. 2021;41:616–624.
16. Alam M, Kakar R, Dover JS, et al. Risk of vascular occlusion associated with usig needles vs cannulas for filler injection. *JAMA Dermatol*. 2021;157:174–180.
17. Carruthers J, Humphrey S, Beleznay K, Carruthers A. A suggested injection zone for soft tissue fillers in the temple. *Dermatol Surg*. 2017;43:756–757.
18. Cotofana S, Gaete A, Hernandez CA, et al. The six different injection techniques for the temple relevant for soft tissue filler augmentation procedures - clinical anatomy and danger zones. *J Cosmet Dermatol*. 2020;19:1570–1579.
19. Cotofana S, Alfertshofer M, Schenck TL, et al. Anatomy of the superior and inferior labial arteries revised: an ultrasound investigation and implication for lip volumization. *Aesthet Surg J*. 2020;40:1327–1335.
20. Cotofana S, Lachman N. Arteries of the face and their relevance for minimally invasive facial procedures: an anatomical review. *Plast Reconstr Surg*. 2019;413:416–426. Erratum in: *Plast Reconstr Surg*. 2019;143:1282–3.
21. Bacigalupi R, Clark J, Lupo MP. An overview of injectable fillers with special consideration to the periorbital area. *Cosmet Dermatol*. 2012;25:421–426.
22. Rohrich RJ, Nguyen AT, Kenkel JM. Lexicon for soft tissue implants. *Dermatol Surg*. 2009;35(Suppl. 2):1605–1611.
23. Rohrich RJ, Ghavami A, Crosby MA. The role of hyaluronic acid fillers (Restylane) in facial cosmetic surgery: review and technical considerations. *Plast Reconstr Surg*. 2007;120(Suppl. 6):41S–54S.
24. Fitzgerald R, Bertucci V, Sykes JM, Duplechain JK. Adverse reactions to injectable fillers. *Facial Plast Surg*. 2016;32:532–555.
25. Pavicic T, Webb KL, Frank K, Gotkin RH, et al. Arterial wall penetration forces in needles versus cannulas. *Plast Reconstr Surg*. 2019;143(3):504e–512ee.
26. Narins RS, Brandt F, Leyden J, et al. A randomized, double-blind, multicenter comparison of the efficacy and tolerability of Restylane versus Zyplast for the correction of nasolabial folds. *Dermatol Surg*. 2003;29:588–595.
27. Baumann LS, Shamban AT, Lupo MP, et al. Comparison of smooth-gel hyaluronic acid dermal fillers with cross-linked bovine collagen: a multicenter, double-masked, randomized, within-subject study. *Dermatol Surg*. 2007;33(Suppl. 2):S128–135.
28. Narins RS, Coleman 3rd WP, Donofrio LM, et al. Improvement in nasolabial folds with a hyaluronic acid filler using a cohesive polydensified matrix technology: results from an 18-month open-label extension trial. *Dermatol Surg*. 2010;36(Suppl. 3):1800–1808.
29. Narins RS, Dayan SH, Brandt FS, Baldwin EK. Persistence and improvement of nasolabial fold correction with nonanimal-stabilized hyaluronic acid 100,000 gel particles/mL filler on two retreatment schedules: results up to 18 months on two retreatment schedules. *Dermatol Surg*. 2008;34(Suppl. 1):S2–S8, discussion S8.
30. Smith SR, Jones D, Thomas JA, et al. Duration of wrinkle correction following repeat treatment with Juvederm hyaluronic acid fillers. *Arch Dermatol Res*. 2010;302:757–762.
31. Micheels P, Besse S, Flynn TC, et al. Superficial dermal injection of hyaluronic acid soft tissue fillers: comparative ultrasound study. *Dermatol Surg*. 2012;38:1162–1169.
32. Black J, Gross TM, Murcia CL, Jones DH. Cohesive polydensified matrix hyaluronic acid for treatment of etched-in fine facial lines: a 6-month open label clinical trial. *Dermatol Surg*. 2018;44:1002–1011.
33. Glogau R, Bank D, Brandt F, et al. A randomized, evaluator-blinded, controlled study of the effectiveness and safety of small gel particle hyaluronic acid for lip augmentation. *Dermatol Surg*. 2012;38:1180–1182.
34. Jones D, Murphy DK. Volumizing hyaluronic acid filler for midface volume deficit: 2-year results from a pivotal single-blind randomized controlled study. *Dermatol Surg*. 2013;39:1602–1612.
35. Humphrey S, Jones DH, Carruthers JD, et al. Retrospective review of delayed adverse events secondary to treatment with a smooth, cohesive 20 mg/ml hyaluronic acid filler in 4500 patients. *J Am Acad Dermatol*. 2020;83:86–95.
36. Monheit G, Kaufman-Janette J, Josepha JH, et al. Efficacy and safety of two resilient hyaluronic acid fillers in the treatment of moderate-to-severe nasolabial folds: a 64-week, prospective, multicenter, controlled, randomized, double-blinded, and within-subject study. *Dermatol Surg*. 2020;46:1521–1529.
37. Kaufman-Janette J, et al. Efficacy and safety of a new resilient hylauronic acid dermal filler, in the correction of moderate-to-severe nasolabial folds: a 64-week, prospective, multicenter, controlled, randomized, double-blind and within-subject study. *J Cosmet Dermatol*. 2019;18:1244–1253.
38. Jones D, Tezel A, Borell M. In-vitro resistance to degradation of HA by ovine testicular hyaluronidase. *Dermatol Surg*. 2010;36:804–809.
39. Shumate G, Chopra R, Jones D, et al. In vivo degradation of crosslinked hyaluronic acid fillers by exogenous hyaluronidases. *Dermatol Surg*. 2018;44:1075–1083.
40. Mazzuco R, Dal'Forno T, Hexsel D. Poly-L-lactic acid for nonfacial skin laxity. *Dermatol Surg*. 2020;46(Suppl 1):S86–S88.
41. Lin M, Dubin DP, Khorasani H. Poly-L-lactic acid for minimally invasive gluteal augmentation. *Dermatol Surg*. 2020;46:386–394.
42. Jones D. Volumizing the face with soft tissue fillers. *Clin Plast Surg*. 2011;38:379–390.
43. Wu D, Goldman MP. The efficacy of massage in reducing nodules formation after poly-L-lactic acid administration for facial volume loss: a randomized, evaluator-blinded clinical trial. *Dermatol Surg*. 2016;42:1266–1272.
44. Goldman M, Moradi A, Katz B, et al. Safety and efficacy of calcium hydroxylapatite dermal filler for hand treatment. *J Am Acad Dermatol*. 2015;72(5):AB20.
45. Smith S, Busso M, McClaren M, Bass LS. A randomized, bilateral, prospective comparison of calcium hydroxylapatite microspheres versus human-based collagen for the correction of nasolabial folds. *Dermatol Surg*. 2007;33(Suppl. 2):S112–S121.
46. Carruthers A, Carruthers J. Evaluation of injectable calcium hydroxylapatite for the treatment of facial lipoatrophy associated with human immunodeficiency virus. *Dermatol Surg*. 2008;34:1486–1499.
47. Busso M, Moers-Carpi M, Storck R, et al. Multicenter, randomized trial assessing the effectiveness and safety of calcium hydroxylapatite for hand rejuvenation. *Dermatol Surg*. 2010;36:790–797.
48. Goldie K, Peeters W, Alghoul M, et al. Global Consensus Guidelines for injection of diluted and hyperdiluted calcium hydroxylapatite for skin tightening. *Dermatol Surg*. 2018;44(suppl 1):S32–S41.
49. Carruthers A, Liebeskind M, Carruthers J, Forster B. Radiographic and computed tomographic studies of calcium hydroxylapatite for treatment of HIV-associated facial lipoatrophy and correction of nasolabial folds. *Dermatol Surg*. 2008;34(s1):S78–S84.
50. Tzikas TL. Autologous fat grafting for midface rejuvenation. *Facial Plast Surg Clin North Am*. 2006;14:229–240.
51. Glogau RG. Microlipoinjection. Autologous fat grafting. *Arch Dermatol*. 1988;124:1340–1343.
52. Pinski KS, Roenigk Jr. HH. Autologous fat transplantation. Long-term follow-up. *J Dermatol Surg Oncol*. 1992;18:179–184.
53. Moscatello DK, Dougherty M, Narins RS, Lawrence N. Cryopreservation of human fat for soft tissue augmentation: viability requires use of cryoprotectant and controlled freezing and storage. *Dermatol Surg*. 2005;31:1506–1510.
54. Carpaneda CA, Ribeiro MT. Percentage of graft viability versus injected volume in adipose autotransplants. *Aesthetic Plast Surg*. 1994;18:17–19.
55. Sadick NS, Hudgins LC. Fatty acid analysis of transplanted adipose tissue. *Arch Dermatol*. 2001;137:723–727.
56. Drake L, Dinehart S, Farmer E, et al. Guidelines of care for soft tissue augmentation: fat transplantation. American Academy of Dermatology. *J Am Acad Dermatol*. 1996;34:690–694.
57. Duffy DM. The silicone conundrum: a battle of anecdotes. *Dermatol Surg*. 2002;28:590–594.
58. Jones DH, Carruthers A, Brody HJ, et al. Ten-year and beyond follow-up after treatment with highly purified liquid-injectable silicone for HIV-associated facial lipoatrophy: a report of 164 patients. *Dermatol Surg*. 2019;45:941–948.
59. Cohen SR, Berner CF, Busso M, et al. Artefill: a long lasting injectable wrinkle filler material – summary of the US Food and Drug Administration trials and a progress report on 4- to 5- year outcomes. *Plast Reconstr Surg*. 2006;118:64S–76S.
60. Kakar R, Minokadeh A, Jones DH. Delayed inflammatory nodules with off-label use of Food and Drug Administration-approved polymethylmethacrylate. *Dermatol Surg*. 2021;47:1030–1031.
61. Jones D. Treatment of delayed reactions to dermal fillers. *Dermatol Surg*. 2014;40:1180.
62. Kang BK, Shin MK, Lee JH, Kim NI. Effects of platelet-rich plasma on wrinkles and skin tone in Asian lower eyelid skin: preliminary results from a prospective randomised, split-face trial. *Eur J Dermatol*. 2014;24:100–101.
63. Abuaf OK, Yildiz H, Baloglu H, et al. Histologic evidence of new collagen formulation using platelet rich plasma in skin rejuvenation: a prospective controlled clinical study. *Ann Dermatol*. 2016;28:718–724.
64. Alam M, Hughart R, Champlain A, et al. Effect of platelet rich plasma injection for rejuvenation of photoaged facial skin: a randomized clinical trial. *JAMA Dermatol*. 2018;154:1447–1452.
65. Du R, Lei T. Effects of autologous platelet-rich plasma injections on facial skin rejuvenation. *Exp Ther Med*. 2020;19:3024–3030.
66. Diaz-Ley B, Cuevast J, Alonso-Castro L, et al. Benefits of plasma rich in growth factors (PRGF) in skin photodamage: clinical response and histological assessment. *Dermatol Ther*. 2015;28:258–263.
67. Hausauer AK, Humphrey S. The physician's guide to platelet-rich plasma in dermatologic surgery part II: clinical evidence. *Dermatol Surg*. 2020;46:447–456.
68. Alam M, Gladstone H, Kramer EM, et al. ASDS Guidelines of care: injectable fillers. *Dermatol Surg*. 2008;34(Suppl. 1):S115–S148.
69. Funt D, Pavicic T. Dermal fillers in aesthetics: an overview of adverse events and treatment approaches. *Clin Cosmet Investig Dermatol*. 2013;6:295–316.
70. Keller EC, Kaminer MS. Use of hyaluronidase in patients with bee allergy. *Dermatol Surg*. 2014;40:1145–1147.
71. Glashofer MD, Flynn TC. Complications of temporary fillers. In: Carruthers J, Carruthers A, eds. *Soft Tissue Augmentation*. Toronto: Elsevier Saunders; 2013:179–187.
72. Humphrey S, Jones DH, Carruthers JD, et al. Retrospective review of delayed adverse events secondary to treatment with a smooth, cohesive 20 mg/ml hyaluronic acid filler in 4500 patients. *J Am Acad Dermatol*. 2020;83:86–95.

Downloaded for Anonymous User (n/a) at Egyptian Knowledge Bank from ClinicalKey.com by Elsevier on March 10, 2024. For personal use only. No other uses without permission. Copyright ©2024. Elsevier Inc. All rights reserved.

73. Jones D, Bank D. Five-year postmarket safety experience with the optimal balance technology of hyaluronic acid filler. *Dermatol Surg*. 2020;46:145–147.
74. Artzi O, Loizides C, Verner I, Landau M. Resistant and recurrent late reaction to hyaluronic acid-based gel. *Dermatol Surg*. 2016;42:31–37.
75. Sadeghpour M, Quatrano NA, Bonati LM, et al. Delayed-onset nodules to differentially crosslinked hyaluronic acids: comparative incidence and risk assessment. *Dermatol Surg*. 2019;45:1085–1094.
76. Beleznay K, Carruthers JD, Carruthers A, et al. Delayed-onset nodules secondary to a smooth cohesive 20 mg/mL hyaluronic acid filler: cause and management. *Dermatol Surg*. 2015;41:929–939.
77. Turkmani MG, De Boulle K, Philipp-Dormston WG. Delayed hypersensitivity reaction to hyaluronic acid dermal filler following influenza-like illness. *Clin Cosmet Investig Dermatol*. 2019;12:277–283.
78. Munavalli GG, Knutsen-Larson S, Lupo MP, Geronemus RG. Oral angiotensin-converting enzyme inhibitors for treatment of delayed inflammatory reactions to dermal hyaluronic acid fillers following COVID-19 vaccination—a model for inhibition of angiotensin II-induced cutaneous inflammation. *JAAD Case Rep*. 2021;10:63–68.
79. Molina-Ruiz AM, Requena L. Foreign body granulomas. *Dermatol Clin*. 2015;33:497–523.
80. Ledon JA, Savas JA, Yang S, et al. Inflammatory nodules following soft tissue filler use: a review of causative agents, pathology and treatment options. *Am J Clin Dermatol*. 2013;14:401–411.
81. Glaich AS, Cohen JL, Goldberg LH. Injection necrosis of the glabella: protocol for prevention and treatment after use of dermal fillers. *Dermatol Surg*. 2006;32:276–281.
82. Lee W, Oh W, Oh SM, Yang EJ. Comparative effectiveness of different interventions of perivascular hyaluronidase. *Plast Reconstr Surg*. 2020;145:957–964.
83. Rauso R, Zerbinati N, Franco R, et al. Cross-linked hyaluronic acid filler hydrolysis with hyaluronidase: different settings to reproduce different clinical scenarios. *Dermatol Ther*. 2020;33:e13269.
84. Li J, Xu Y, Wang Y, et al. The role of hyaluronidase for the skin necrosis caused by hyaluronic acid injection-induced embolism: a rabbit auricular model study. *Aesthetic Plast Surg*. 2019;43:1362–1370.
85. Ciancio F, Tarico MS, Giudice G, Perrotta RE. Early hyaluronidase use in preventing skin necrosis after treatment with dermal fillers: report of two cases. *F1000Res*. 2018;7:1388.
86. Fang M, Rahman E, Kapoor KM. Managing complications of submental artery involvement after hyaluronic acid filler injection in chin region. *Plast Reconstr Surg Glob Open*. 2018;6:e1789.
87. Juhász ML, Marmur ES. Temporal fossa defects: techniques for injecting hyaluronic acid filler and complications after hyaluronic acid filler injection. *J Cosmet Dermatol*. 2015;14:254–259.
88. Cohen JL, Biesman BS, Dayan SH, et al. Treatment of hyaluronic acid filler-induced impending necrosis with hyaluronidase: consensus recommendations. *Aesthet Surg J*. 2015;35:844–849.
89. Beleznay K, Humphrey S, Carruthers JD, Carruthers A. Vascular compromise from soft tissue augmentation: experience with 12 cases and recommendations for optimal outcomes. *J Clin Aesthet Dermatol*. 2014;7:37–43.
90. Alam M, Hughart R, Geisler A, et al. Effectiveness of low doses of hyaluronidase to remove hyaluronic acid filler nodules: a randomized clinical trial. *JAMA Dermatol*. 2018;154:765–772.
91. Alam M, Dover JS. Management of complications and sequelae with temporary injectable fillers. *Plast Reconstr Surg*. 2007;120(6 Suppl):98S–105S.
92. Lee W, Oh W, Oh SM, Yang EJ. Comparative effectiveness of different interventions of perivascular hyaluronidase. *Plast Reconstr Surg*. 2020;145(4):957–964.
93. Robinson DM. In vitro analysis of the degradation of calcium hydroxylapatite dermal filler: a proof-of-concept study. *Dermatol Surg*. 2018;44:S5–S9.
94. Rullan PP, Olson R, Lee KC. The use of intralesional sodium thiosulfate to dissolve facial nodules from calcium hydroxylapatite. *Dermatol Surg*. 2020;46:1366–1368.
95. DeLorenzi C. Complications of injectable fillers, part 2: vascular complications. *Aesthet Surg J*. 2014;34:584–600.
96. Dayan S, Arkins JP, Mathison CC. Management of impending necrosis associated with soft tissue filler injections. *J Drugs Dermatol*. 2011;10:1007–1012.
97. DeLorenzi C. Complications of injectable fillers, part I. *Aesthet Surg J*. 2013;3:561–575.
98. Park SW, Woo SJ, Park KH, et al. Iatrogenic retinal artery occlusion caused by cosmetic facial filler injections. *Am J Ophthalmol*. 2012;154:653–662.
99. Ozturk CN, Li Y, Tung R, et al. Complications following injection of soft-tissue fillers. *Aesthet Surg J*. 2012;33:862–877.
100. Tobalem S, Schutz JS, Chronopoulos A. Central retinal artery occlusion – rethinking retinal survival time. *BMC Ophthalmol*. 2018;18:101.
101. Lee W, Koh IS, Oh W, Yang EJ. Ocular complications of soft tissue filler injections: a review of literature. *J Cosmet Dermatol*. 2020;19:772–781.
102. Surek CC, Said SA, Perry JD, Zins JE. Retrobulbar injection for hyaluronic acid gel filler-induced blindness: a review of efficacy and technique. *Aesth Plast Surg*. 2019;43:1034–1040.
103. Paap MK, Milman T, Ugradar S, et al. Examining the role of retrobulbar hyaluronidase in reversing filler-induced blindness: a systematic review. *Ophthalmic Plast Reconstr Surg*. 2020;36:231–238.

Downloaded for Anonymous User (n/a) at Egyptian Knowledge Bank from ClinicalKey.com by Elsevier on March 10, 2024. For personal use only. No other uses without permission. Copyright ©2024. Elsevier Inc. All rights reserved.

eFig. 158.1 Hyaluronic acid – augmentation of nasolabial folds, lips, and oral commissures. A, B Pre-treatment. **C, D** Following injection of Juvéderm Ultra®.

eFig. 158.2 Poly-L-lactic acid – correction of facial fat loss. A Pre-treatment in a patient with facial fat loss related to aging and lean body mass. **B** Eight months post-treatment of the cheeks (and temples) with 10 vials of Sculptra® (five treatments, two vials per treatment) over 4 months.

Downloaded for Anonymous User (n/a) at Egyptian Knowledge Bank from ClinicalKey.com by Elsevier on March 10, 2024. For personal use only. No other uses without permission. Copyright ©2024. Elsevier Inc. All rights reserved.

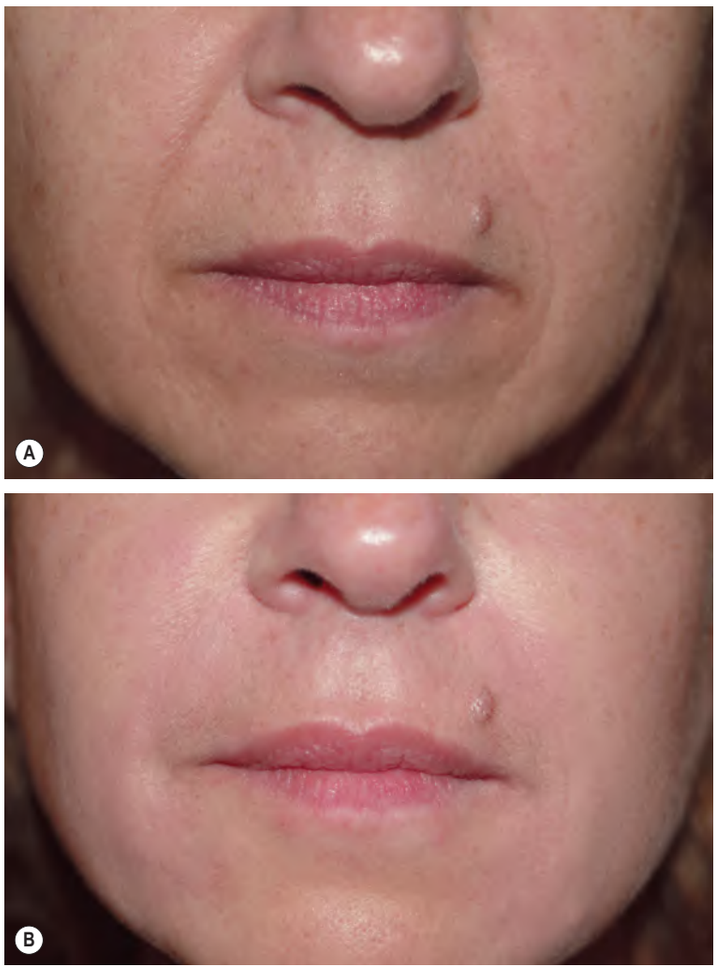

eFig. 158.3 Calcium hydroxylapatite – perioral augmentation. A Prior to injection of 1 ml of Radiesse®. **B** Follow-up: softening of nasolabial fold and elevation of lateral oral commissure. *Courtesy Seth L. Matarasso, MD*.

eFig. 158.4 Calcium hydroxylapatite – correction of facial fat loss. A Pre-treatment in a patient with facial fat loss related to aging and lean body mass. **B** Following injection of Radiesse® into the midface.

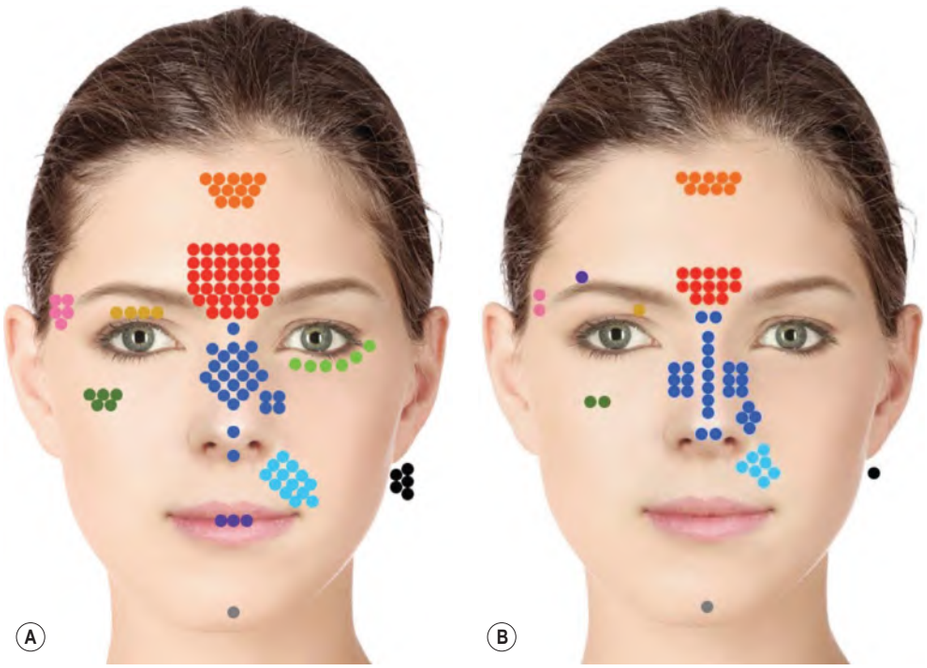

eFig. 158.5 Location of filler injection in reported cases of blindness. A 98 patients (2015). **B** 48 patients (2019). The black dots represent cases in which the location was simply listed as "face". *A, Reproduced with permission from Beleznay K, Carruthers JD, Humphrey S, Jones D. Avoiding and treating blindness from fillers: a review of the world literature. Dermatol Surg 2015;41:1097-117. B, Reproduced with permission from Beleznay K, Carruthers JDA, Humphrey S, et al. Update on avoiding and treating blindness from fillers: a recent review of the world literature. Aesthet Surg J 2019;39:662–74*.

Downloaded for Anonymous User (n/a) at Egyptian Knowledge Bank from ClinicalKey.com by Elsevier on March 10, 2024. For personal use only. No other uses without permission. Copyright ©2024. Elsevier Inc. All rights reserved.